

## CASE REPORT

# Treatment of female pattern hair loss with the androgen receptor antagonist flutamide

Anosha Yazdabadi and Rod Sinclair

*Department of Dermatology, St. Vincent's Hospital Melbourne and Department of Medicine, St. Vincent's Hospital, University of Melbourne, Melbourne, Victoria, Australia*

### ABSTRACT

Female pattern hair loss is a common but difficult to manage condition. Commonly used treatments include oral antiandrogens such as spironolactone and topical minoxidil. The response to treatment is variable. We report a woman whose hair loss progressed while using spironolactone and topical minoxidil in combination, but reversed with flutamide, a potent androgen receptor antagonist.

### INTRODUCTION

The binding of dihydrotestosterone (DHT) to hair follicle androgen receptors has been clearly implicated in the pathogenesis of male pattern hair loss (MPHL).<sup>1</sup> Treatment with the 5 $\alpha$  reductase inhibitors finasteride and dutasteride, which reduce DHT synthesis, arrests MPHL and stimulates hair regrowth.<sup>2</sup> Functional polymorphism of the androgen receptor (AR) confers the risk of premature MPHL and predicts treatment response to finasteride.<sup>1,2</sup>

In contrast, the role of androgens in female pattern hair loss (FPHL) has not been clearly established. No association between polymorphism of the AR and FPHL has been identified to date. Case series' support the use of androgen receptor inhibitors such as spironolactone and cyproterone acetate; however randomized placebo-controlled trials have not been performed.<sup>3</sup> Patient responses to 5 $\alpha$  reductase inhibitor treatment is variable and unpredictable.<sup>4,5</sup>

It is not clear whether the variable response is due to differences in the pathogenesis of MPHL and FPHL, the difficulty of measuring treatment response, or potency of spironolactone and cyproterone acetate as antiandrogens.<sup>6</sup>

Flutamide is a potent orally administered antiandrogen that works by inhibiting uptake and binding of androgens to

receptors.<sup>7</sup> There is evidence that flutamide is effective in the treatment FPHL in hyperandrogenic women.<sup>8</sup>

### CASE REPORT

A 35-year-old woman presented initially with a 15-year history of increased hair shedding and decreased hair density. On examination she had diffuse hair loss with widening of the midline part, consistent with Sinclair grade 4 (Fig. 1). Baseline full blood count, liver function, renal function, thyroid function and serum ferritin were all within the normal range. Serum testosterone, free androgen index and dehydroepiandrosterone sulfate were also normal. Three, 4 mm scalp punch biopsies taken from adjacent skin on the mid-frontal scalp all showed significant hair follicle miniaturization with a terminal to vellus hair count of less than 4:1 (2.2:1, 1.1:1 and 1:1.5), consistent with androgenetic alopecia.<sup>9</sup>

Treatment with oral spironolactone at a dose of 200 mg per day was well tolerated; however she failed to show any significant improvement over the next 5 years despite evidence of a cutaneous antiandrogen effect with almost complete loss of secondary sexual hair. Minoxidil 5%, 1 mL topically daily was added to the treatment regimen however after 6 months of continuous usage there was no significant clinical improvement.

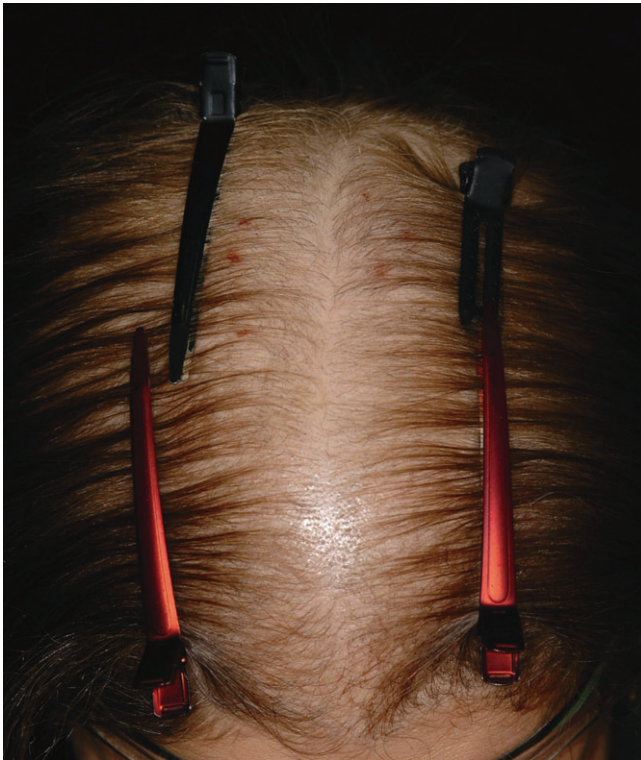Flutamide 250 mg peroral daily was commenced. Spironolactone was ceased while the topical minoxidil was continued. The patient reported decreased hair shedding and increased hair density over the frontal scalp over the next 12 months. On examination the hair loss score improved from Sinclair stage 4 to Sinclair stage 2. Similar improvement was noted on serial scalp photography (Fig. 2). Flutamide was well tolerated. Serial liver function tests were normal.

### Abbreviations:

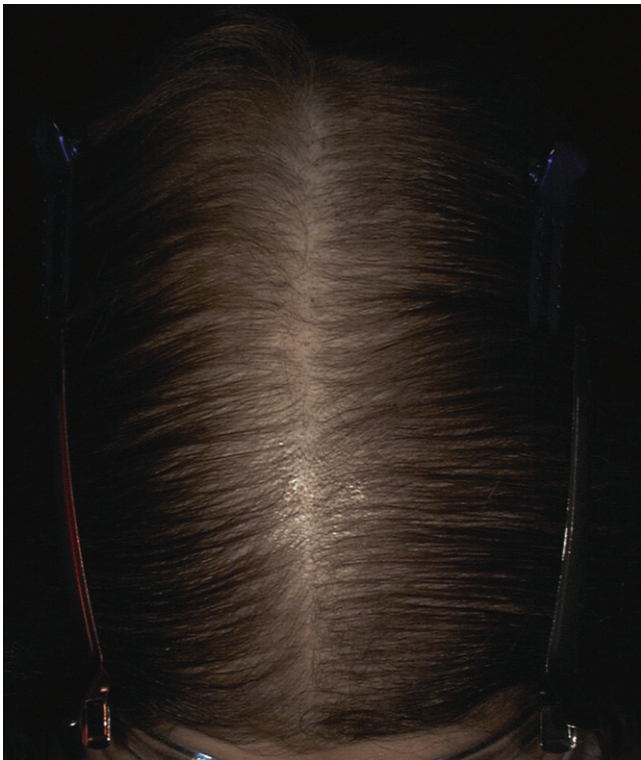
DHT	dihydrotestosterone
MPHL	male pattern hair loss
AR	androgen receptor
FPHL	female pattern hair loss

Correspondence: Dr Anosha Yazdabadi, Department of Dermatology, Level 9 Aikenhead Bldg, PO Box 2900, Fitzroy VIC 3065, Australia. Email: yazdaa27@gmail.com

Submitted 15 November 2010; accepted 5 December 2010.



**Figure 1** Baseline global scalp photograph demonstrating Sinclair grade 4 hair loss.



**Figure 2** Global scalp photograph after 12 months of treatment with flutamide demonstrating an improvement to Sinclair grade 2 hair loss.

## CONCLUSION

The aetiology of FPHL is controversial. Although studies have failed to show consistently elevated circulating androgen levels to be associated with this disease entity,<sup>10</sup> there is evidence of response to oral antiandrogen therapy.<sup>5</sup> The mechanism action of flutamide is believed to be potent inhibition of androgen uptake and inhibition of binding of androgens to target tissue.<sup>7</sup> Flutamide has been shown to be effective in the treatment of hirsutism and FPHL in women with hyperandrogenic states.<sup>8</sup> Spironolactone has only moderate antiandrogenic activity.<sup>11</sup> The main mechanism of action of spironolactone is inhibition of the interaction between dihydrotestosterone and the intracellular androgen receptor.<sup>11</sup>

While the possibility of a delayed response to the introduction of topical minoxidil was considered, this was thought unlikely due to the normal time course for treatment response to topical minoxidil described in clinical trials. Hair growth usually commences from 8 weeks of treatment and reaches a maximum after 6 months. Thereafter no additional regrowth is detected.<sup>12</sup>

This report documents the therapeutic response of FPHL to flutamide in a patient who has failed to respond to spironolactone. The most likely explanation is that FPHL is due to increased end organ sensitivity to circulating androgens and flutamide is a more potent androgen receptor antagonist than spironolactone. While we still advocate spironolactone as a first-line therapy for FPHL, flutamide can be considered as a second-line treatment in non-responders. Patients should be warned about the potential of liver toxicity and serial liver function monitoring is required.<sup>7</sup>

## REFERENCES

1. Hayes VM, Severi G, Padilla EJ *et al*. 5 $\alpha$ -Reductase type 2 gene variant associations with prostate cancer risk, circulating hormone levels and androgenetic alopecia. *Int. J. Cancer*. 2007; **120**: 776–80.
2. Olsen EA, Hordinsky M, Whiting D *et al*. The importance of dual 5 $\alpha$ -reductase inhibition in the treatment of male pattern hair loss: results of a randomized placebo-controlled study of dutasteride versus finasteride. *J. Am. Acad. Dermatol.* 2006; **55**: 1014–23.
3. Sinclair R, Wewerinke M, Jolley D. Treatment of female pattern hair loss with oral antiandrogens. *Br J Dermatol.* 2005; **152**: 466–73.
4. Thai KE, Sinclair RD. Finasteride for female androgenetic alopecia. *Br. J. Dermatol.* 2002; **147**: 812–3.
5. Price VH, Roberts JL, Hordinsky M *et al*. Lack of efficacy of finasteride in postmenopausal women with androgenetic alopecia. *J. Am. Acad. Dermatol.* 2000; **43**: 768–76.
6. Birch MP, Lashen H, Agarwal S *et al*. Female pattern hair loss, sebum excretion and the end-organ response to androgens. *Br. J. Dermatol.* 2006; **154**: 85–9.
7. MIMS Online. *Prescribing information, Flutamide*, Available from URL: [https://www.mimsonline.com.au/Search/FullPI.aspx?ModuleName=ProductInfo&searchKeyword=Flutamide&PreviousPage=~/Search/QuickSearch.aspx&SearchType=&ID=10260001\\_2](https://www.mimsonline.com.au/Search/FullPI.aspx?ModuleName=ProductInfo&searchKeyword=Flutamide&PreviousPage=~/Search/QuickSearch.aspx&SearchType=&ID=10260001_2). (Accessed 11 May 2010).
8. Carmina E, Lobo RA. Treatment of hyperandrogenic alopecia in women. *Fertil. Steril.* 2003; **79**: 91–5.

9. Messenger AG, Sinclair R. Follicular miniaturization in female pattern hair loss: clinicopathological correlations. *Br. J. Dermatol.* 2006; **155**: 926–30.
10. Birch MP, Lalla SC, Messenger AG. Female pattern hair loss. *Clin. Exp. Dermatol.* 2002; **27**: 583–88.
11. MIMS Online. *Prescribing Information. Spironolactone*, Available from URL: [https://www.mimsonline.com.au/Search/FullPL.aspx?ModuleName=ProductInfo&searchKeyword=spironolactone&PreviousPage=-/Search/QuickSearch.aspx&SearchType=&ID=7700001\\_2](https://www.mimsonline.com.au/Search/FullPL.aspx?ModuleName=ProductInfo&searchKeyword=spironolactone&PreviousPage=-/Search/QuickSearch.aspx&SearchType=&ID=7700001_2) (Accessed 11 May 2010).
12. Lucky AW, Piacquadio DJ, Ditre CM *et al.* A randomized, placebo-controlled trial of 5% and 2% topical minoxidil solutions in the treatment of female pattern hair loss. *J. Am. Acad. Dermatol.* 2004; **50**: 541–53.